

ORIGINAL ARTICLE

Endoscopic Management of Paranasal Sinus Mucoceles: Experience With 46 Patients^{☆,☆☆}

Rodolfo Nazar,^{a,*} Alfredo Naser,^a Javiera Pardo,^a Juan Fulla,^a Jesús Rodríguez-Jorge,^b Paul H. Delano^a

^a Servicio de Otorrinolaringología, Hospital Clínico de la Universidad de Chile, Santiago, Chile

^b ENT University Hospital, Eberhard-Karls-Universität, Department of Otolaryngology and Head and Neck Surgery, Tuebingen, Germany

Received 26 January 2011; accepted 20 April 2011

KEYWORDS

Mucoceles;
Endoscopic sinus
surgery;
Latin America

Abstract

Objective: The purpose of this study was to determine changes in the surgical treatment of patients with the diagnosis of paranasal mucoceles managed in a Latin American hospital. We hypothesised that endonasal endoscopic surgeries had emerged as the main treatment option for this disease in the last five years.

Methods: A retrospective chart review of all patients who were diagnosed with paranasal sinus mucoceles and treated at the Otorhinolaryngology Head and Neck Department of our hospital from 2002 to 2010 was performed. Patient demographic data, mucoceles location, symptoms, surgical approach and complications were recorded.

Results: A total of 46 patients were included (27 males; 19 females). This series include 29 patients (63%) with frontal or fronto-ethmoidal mucoceles, 14 (30.4%) with maxillary and 3 (6.5%) with sphenoid mucoceles. Ninety-five percent of the patients were treated with intranasal endoscopic surgery. Complications occurred only in 7 cases (15.2%).

Conclusions: This study confirms that over the last 9 years significant changes have occurred in the surgical treatment of paranasal mucocele in our hospital, as endoscopic surgeries increased from 34% to over 90% as the first option of treatment for mucoceles.

© 2011 Elsevier España, S.L. All rights reserved.

[☆] Please cite this article as: Nazar R, et al. Manejo endoscópico de mucoceles de senos paranasales: experiencia en 46 pacientes. Acta Otorrinolaringol Esp. 2011;62:363–6.

^{☆☆} Part of this work was presented, and received an award as the best poster, at the 7th Meeting of the German-Spanish Otolaryngology and Head and Neck Surgery Society, held in Freiburg, Germany (September 2007).

* Corresponding author.

E-mail address: rnazars@gmail.com (R. Nazar).

PALABRAS CLAVE

Mucoceles;
Cirugía endoscópica
endonasal;
Latinoamérica

Manejo endoscópico de mucocelos de senos paranasales: experiencia en 46 pacientes**Resumen**

Objetivo: El propósito de este estudio es determinar los cambios en el tratamiento quirúrgico de los pacientes con diagnóstico de mucocele paranasal manejados en un hospital terciario de Latinoamérica. Nuestra hipótesis es que en los últimos ocho años la cirugía endoscópica endonasal ha emergido como la principal opción de tratamiento para esta patología.

Material y métodos: Estudio retrospectivo descriptivo de todos los pacientes que fueron diagnosticados y tratados por mucocele de seno paranasal en el Departamento de Otorrinolaringología y Cirugía de Cabeza y Cuello de nuestro hospital durante los años 2002 al 2010. Se registraron datos demográficos de los pacientes, localización del mucocele, síntomas, abordaje quirúrgico y complicaciones.

Resultados: Se incluyeron un total de 46 pacientes (27 de sexo masculino y 19 femenino). Esta serie comprendió 29 pacientes con mucocele frontal o frontoetmoidal (63%), 14 con mucocele maxilar (30,4%) y 3 pacientes con mucocele esfenoidal (6,5%). El 95% de los pacientes fueron tratados con cirugía endoscópica endonasal. Sólo 7 casos presentaron complicaciones (15,2%).

Conclusiones: Este estudio confirma que en los últimos 9 años ha ocurrido un cambio significativo en el tratamiento quirúrgico de los mucocelos de cavidades paranasales, con un aumento de la cirugía endoscópica de un 34% a más de un 90%, siendo la primera opción de tratamiento.

© 2011 Elsevier España, S.L. Todos los derechos reservados.

Introduction

Mucoceles are benign masses located in the paranasal cavities. Their origin is probably secondary to obstruction of the ostium of the paranasal sinuses and they are described as epithelial sacks containing mucus secretion and occupying the paranasal sinuses.¹ The most common location of mucocelos are the frontal and fronto-ethmoidal sinuses, although they can also be found in the maxillary and sphenoid sinuses.² They cause slow, progressive expansion and dilatation of the sinuses, producing symptoms, such as headache, nasal obstruction, facial pain, decreased visual acuity, diplopia, displacement of the eyeball and facial edema.^{1,2} With regard to treatment, endoscopic endonasal surgery is currently the most commonly used surgical approach in Europe and the U.S.A.²⁻⁶ In Latin America, there are few published studies regarding the surgical management of paranasal mucocelos.⁷⁻⁹ A 2003 study by Celedón et al. conducted at our hospital showed that external frontotomy was the most frequently used surgical technique for treatment of mucocelos.⁷ Another 2 studies carried out in Brazil by Oliveira et al.⁸ and Santos et al.⁹ reported 2 and 13 cases of fronto-ethmoidal mucocelos, respectively, which were successfully treated by endoscopic endonasal surgery. However, it has not yet been established whether endoscopic surgery of paranasal mucocelos is the treatment of choice in Latin America. Therefore, we decided to analyse the frequency and type of surgical procedures performed at our hospital on patients with a diagnosis of paranasal mucocelos in the past 8 years (2002–2010). We classified the location and symptoms in all patients with diagnosis of paranasal mucocele, to demonstrate changes in the surgical procedure and approach.

Material and Methods

We performed a retrospective descriptive study of all patients diagnosed with paranasal mucocele from 2002

to 2010 at a tertiary institution. Our sample included 46 patients with diagnosis of paranasal mucocele. We analysed the surgical approach and postoperative complications according to the type of surgery performed in each case. We recorded the demographic data of patients, including location of the mucocele, symptoms, and surgical approach. The location and extent of the paranasal mucocelos were defined through computed tomography. We described postoperative complications through a follow-up period ranging from 1 to more than 8 years. Data were recorded on an Excel[®] spreadsheet and descriptive statistics were carried out. Lastly, we compared our results with a previous study carried out at our hospital between 1992 and 2002.⁷

Results

The age range of the 46 patients was 16–85 years (mean age: 50.36±19.9 years). The most affected sinus was the fronto-ethmoidal complex (63%), followed by the maxillary sinus (30.4%) and the sphenoid sinus (6.5%) (Table 1). The main symptoms were: increase of periocular volume in frontal mucocelos (51.7%), rhinorrhoea in maxillary mucocelos (51.1%) and headache in all patients with sphenoid mucocele (100%) (Table 2). In total, 11 of the 21 patients (37.9%) with fronto-ethmoidal mucocele and all 3 patients with sphenoid mucocele were referred from the Neurosurgery, Ophthalmology or Endocrinology Departments. On the other hand, almost all patients with maxillary mucocele (7 of 8) were diagnosed during a first consultation at the Otolaryngology Department.

Most patients were treated with nasal endoscopic surgery exclusively (87%). A total of 4 patients required a combined approach (external plus endoscopic) (8.7%) and only 2 cases of fronto-ethmoidectomy (4.3%). External surgery was performed exclusively for the management of the frontal sinus in 6 patients. The indications for external surgery were: prominent frontal spine, narrow frontal sinus in its

Table 1 Description of the Location of Paranasal Mucoceles.

Location of Mucocele	Affected Side	Number	Percentage
Fronto-ethmoidal	Left	13	28.3
	Right	14	30.4
	Bilateral	2	4.3
	Total	29	63
Maxillary	Left	11	23.9
	Right	2	4.3
	Bilateral	1	2.2
	Total	14	30.4
Sphenoid	Left	1	2.2
	Right	2	4.3
	Bilateral	0	0
	Total	3	6.5

Table 2 Symptoms Related to the Location of Mucoceles.

Location of Mucocele	Symptoms	Percentage
Fronto-ethmoidal (n=29)	Increase of ocular volume	51.7
	Headache	41.4
Maxillary (n=14)	Rhinorrhoea	57.1
	Nasal obstruction	28.6
	Posterior nasal discharge	28.6
Sphenoid (n=3)	Headache	100.0
	Rhinorrhoea	33.3

anterior–posterior diameter and impossibility to manage the frontal recess endoscopically.

Seven patients suffered postoperative complications (15.2%). Most of them (6 of 7) were mild epistaxis following endoscopic surgery, which was reviewed by the anterior tamponade. Only one patient presented a major complication, which was endophthalmitis secondary to external surgery (Lynch frontotomy). This was resolved with review surgery and appropriate antibiotic management.

All patients were evaluated by clinical and endoscopic controls at least twice after the surgical procedure. The minimum follow-up period was 1 year, showing the treated sinus to be permeable to endoscopy in all cases. **Figs. 1 and 2** show images of a female patient with a bilateral fronto-ethmoidal mucocele who was treated exclusively with nasal endoscopic surgery.

Discussion

In this study, as in others, we found that the most common location of paranasal mucoceles was the fronto-ethmoidal sinus (67.7%), followed by the maxillary sinus.^{2,5,6} Minor complications occurred in 15.2% of patients. Major complications occurred in 1 case, which required review surgery and appropriate antibiotic management.

Although we did not have a neuronavigator, there were no cases of meningoencephalitic complications.

We observed no restenosis of the ostium in the treated paranasal sinuses in any of the patients. Special emphasis was placed on endoscopic control of the frontal sinus. However, it is important to note that long-term monitoring is essential in these patients due to the risk of restenosis.²

Mucocele management before the 1990s was handled through external fronto-ethmoidectomy, with or without placement of a stent in the nasofrontal duct. At present, most surgeons prefer a nasal endoscopic approach exclusively. The benefits of this technique are the preservation of the framework of the involved sinus, decreased surgical time, avoidance of the external incisions and reduced hospitalisation costs.^{2,4,10,11}

The results of the present study show a clear preference for endoscopic management of paranasal mucoceles at our hospital in the past 8 years. A previous study at our department (1992–2001), with 35 patients treated for paranasal mucoceles, showed that only 34% of patients underwent endoscopic nasal surgery.⁷ In contrast, the present study shows that over 85% of patients were treated with endoscopic surgery exclusively.

Endoscopic mucocele management has the advantage of allowing a less traumatic approach, as well as reducing morbidity rates and operative time to a minimum. Therefore, endoscopic surgery is becoming the surgical technique of choice. All procedures were performed according to institutional bioethics norms.

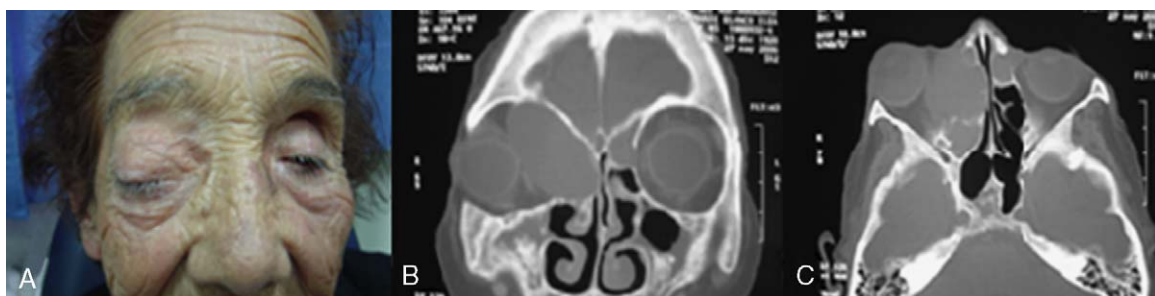

Figure 1 (A) Face of an 85-year-old woman, with a history of 5 years of holocranial headache and ocular protrusion with loss of vision; (B) CT scan of the paranasal sinuses, coronal section; and (C) axial section, showing bilateral fronto-ethmoidal mucocele, larger on the right side, with ocular protrusion and compression of adjacent structures.

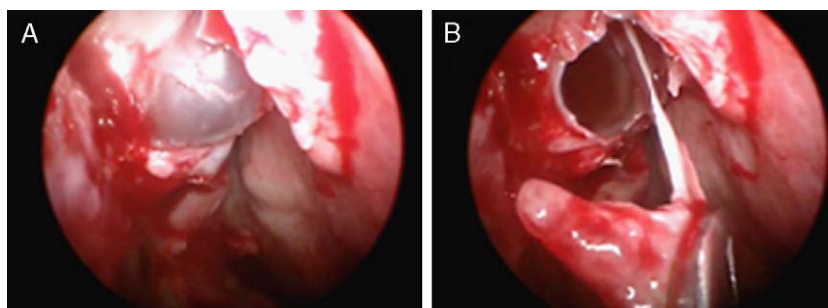


Figure 2 (A) Image of the right fronto-ethmoidal mucocoele in functional endoscopic surgery of the paranasal sinuses. We found that the right middle turbinate was displaced by the lateral nasal wall. We performed partial turbinectomy. (B) The right fronto-ethmoidal cells were opened, the mucocoele was identified and its capsule was marsupialised. Purulent discharge was drained from the inside, leaving the periorbit exposed.

Conflict of Interests

The authors have no conflicts of interest to declare.

References

1. Lund VJ, Milroy CM. Fronto-ethmoidal mucocoeles: a histopathological analysis. *J Laryngol Otol.* 1991;105:921–3.
2. Har-El G. Endoscopic management of 108 sinus mucocoeles. *The Laryngoscope.* 2001;111:2131–4.
3. Busaba NY, Salman SD. Maxillary sinus mucocoeles: clinical presentation and long-term results of endoscopic surgical treatment. *The Laryngoscope.* 1999;109:1446–9.
4. Caylakli F, Yavuz H, Can Cagici A, Naci Ozluoglu L. Endoscopic sinus surgery for maxillary sinus mucocoeles. *Head Face Med.* 2006;2:29.
5. Bockmühl U, Kratzsch B, Benda K, Draf W. Paranasal sinus mucocoeles: surgical management and long term results. *Laryngorhinotologie.* 2005;84:892–8.
6. Bockmühl U, Kratzsch B, Benda K, Draf W. Surgery for paranasal sinus mucocoeles: efficacy of endonasal micro-endoscopic management and long-term results of 185 patients. *Rhinology.* 2006;44:62–7.
7. Celedón C, Inzunza F, Olavarría C, Silva C, Tamblay N, Tapia L. Estudio y manejo de mucocoeles de cavidades perinasales. *Rev Otorrinolaringol Cir Cabeza Cuello.* 2003;63:29–34.
8. Oliveira A, Gonzaga A, Narutomo E, Akaki F, Sampaio A, Matsumaya C. Mucocele frontoetmoidal: relato de casos e revisao da literature. *Rev Bras Otorrinolaringol.* 2004;70:850–4.
9. Santos RP, Barbosa LHF, Belfort MA, Ferri RG, Gregorio LC. Acceso endoscopico para tratamiento de mucocoeles frontoetmoidais. *Rev Bras Otorrinolaringol.* 2002;68:326–9.
10. Pino V, Trinidad G, Álvarez J, Carrasco F, Blasco A. Mucocoeles de los senos paranasales. Presentación de 10 casos y revision de la literature. *ORL dips.* 2005;32:26–9.
11. Marks SC, Latoni JD, Mathog RH. Mucocoeles of the maxillary sinus. *Otolaryngol Head Neck Surg.* 1997;117:18–21.